

**Pediatric and Adolescent
Foot and Ankle Care**
at Foot and Ankle Center of Washington

Douglas S. Hale, DPM
Lawrence Z. Huppin, DPM

Children and adolescents experience a variety of foot and ankle problems. From congenital disorders, such as severe flatfoot, to sports injuries, to ingrown nails. It's essential that your children get highly capable, results-oriented attention.

Feet suffer tremendous force every day and today's problems can worsen over time. This can negatively affect your child's physical, social and psychological development. We love kids, and we devote ourselves to the mechanics of their feet and ankles because we want them to have the most positive results over the long term.



Tel: 206 344 3808

Fax: 206 860 0907

www.footankle.com

600 Broadway, Suite 220
Seattle, WA 98122

Dr. Douglas S. Hale

Douglas S. Hale, DPM graduated with honors from both Tulane University School of Engineering and the Dr. William Scholl M. College of Podiatric Medicine. Upon completion of his Podiatric Medical degree, he pursued a residency in reconstructive foot and ankle surgery.

Dr. Hale's residency program, currently based at Swedish Medical Center-Providence campus, was and still is rated among the top five in the United States and only accepts two residents yearly. The residency program provides extensive clinical and hospital experience in both common and complex conditions of the foot and ankle and many other areas including podiatric family and sports medicine, as well as reconstructive foot and ankle surgery. In addition he has specialized training in orthotic therapy. He is successful in treating most foot and ankle conditions with conservative therapy, but when necessary has the expertise to make surgical corrections.

Dr. Hale, who is triple-board certified, has been in private practice in Seattle for over 10 years, treating simple to complex foot and ankle disorders. In 2003, he was elected by his colleagues as Chief of Podiatric Staff, Swedish Medical Center, Seattle, WA and remains actively involved in the residency program as Extern Director. He lectures to physicians and students regionally on a variety of topics and has received numerous awards.

Dr. Lawrence Z. Huppin

Lawrence Z. Huppin, DPM earned his medical degree at the California College of Podiatric Medicine. Following graduation he completed a podiatric medical residency.

In 1989 he was one of two podiatrists to be accepted into the California College of Podiatric Medicine *Fellowship in Podiatric Biomechanics*. This one-year program, the only of its kind in the nation, consisted of extensive training in foot and body mechanics, focusing on the areas of orthotic therapy, sports medicine, and children's foot conditions.

In 1993, Dr. Huppin became board certified by the American Board of Podiatric Orthopedics. In 2000 he was the Washington State Podiatric Physician of the Year. In 2002 he was became an associate professor in the department of biomechanics at the California College of Podiatric Medicine. In 2004 he was named a "Seattle Top Doctor" in Seattle Magazine's annual survey of medical professionals..

Dr. Huppin is a nationally recognized lecturer and teacher on orthotic therapy and biomechanics. Along with his private practice, he is the director of the *Institute for Orthotic Therapy Education* – a Bay Area based organization that provides education on orthotic therapy to doctors and medical students throughout North America. In this capacity, he provides education, consultation and instruction to other doctors on the best techniques of conservative foot and ankle therapy.



**Heel Pain
in
Children**



**Pediatric and Adolescent
Foot and Ankle Care**
at Foot and Ankle Center of Washington

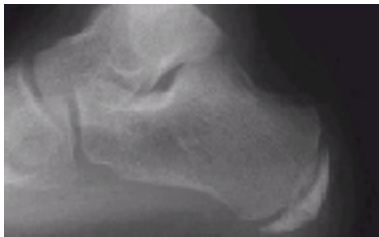
Heel Pain in Children

What is heel pain in children

Heel pain is uncommon in children. Children who do get heel pain, the most common cause is a disturbance to the growing area at the back of the heel bone (calcaneus) where the strong Achilles tendon attaches to it. This is known as **Sever's disease** or **calcaneal apophysitis** (inflammation of the growth plate). Apophysitis is most common between the ages of 10 to 14 years of age. This is one of several different 'osteochondroses' that can occur in the body, such as at the knee (Osgood-Schlatters Disease).

The anatomy of Calcaneal Apophysitis

When a baby is born, most of the bones are still cartilage with only some starting to develop into bone. When the heel (calcaneus) starts to develop bone, there is generally one large area of development that starts in the center of the cartilage heel. This area of bone spreads to 'fill up' the cartilage. Another area of bone development (ossification) occurs at the back of the heel bone - see the x-ray to the right. These two areas of developing bone will have an area of cartilage between them - this is how the bone grows in size. At around age 16, when growth is nearly complete, these two bony areas fuse together. Calcaneal apophysitis is usually considered to be due to damage or a disturbance in this area of growth



Symptoms

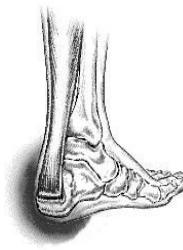Pain is usually felt at the back and side of the heel bone. Sometimes there may be pain at the bottom of the heel. The pain is usually relieved when the child is not active and becomes painful with sport. Squeezing the sides of the heel bone is often painful. Running and jumping make the symptoms worse. One or both heels can be affected. In more severe cases, the child may be limping.



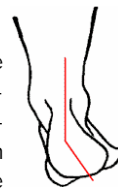Causes

The cause of calcaneal apophysitis is not entirely clear. It is likely due to repeated minor trauma that happens in a lot of sporting activities - the cartilage joint between the two parts of the bone can not take all the stress of the activities. Some children seem to be more prone to apophysitis for unknown reasons - combine this with sport, especially if it is on a hard surface and the risk of developing apophysitis increases. Children who are heavier are also at greater risk for developing calcaneal apophysitis.

A tight calf muscle is also common in those who develop calcaneal apophysitis. If you look at the picture, you can imagine how much pull there is from the calf muscles via the Achilles tendon on the small growth plate at the back of the heel. The strain that this will place on the growth plate is significant



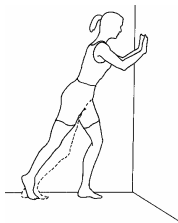
A **pronated foot** (a foot rolled in at the ankle) has also been shown to make calcaneal apophysitis more likely. It is assumed that this may cause an uneven weight bearing on the back part of the heel bone.



Self management of calcaneal apophysitis

If your child has calcaneal apophysitis, the following is suggested:

- Cut back on sporting activities - don't stop, just reduce the amount until symptoms improve (if the condition has been present for a while, a total break from sport may be needed later)
- Avoid going barefoot
- A heel lift or arch support is very important (this reduces the pull from the calf muscles on the growth plate and increases the shock absorption, to reduce growth plate irritation).
- Stretch the calf muscles provided the stretch does not cause pain in the area of the growth plate.
- The use of an ice pack after activity for 20mins is often useful for calcaneal apophysitis - this should be repeated 2 to 3 times a day.



Podiatric management

Management by a health professional of calcaneal apophysitis is often wise. There are a few very rare problems that may be causing the pain, so a correct diagnosis is important.

BIOMECHANICAL CONTROL

A **pronated foot** is common in children with this problem, so the use of prefabricated or custom foot orthotics may be important to prevent correct the excessive pronation and reduce pull from the calf muscle.



If this initial therapy is not effective, we can modify OTC arch supports to further decrease pull from the calf muscles or, in cases of more severe biomechanical abnormality, put the child into custom foot orthoses.

In rare cases the lower limb may need to be put in a cast for 2-6 weeks to give the growth plate a chance to heal.

After the calcaneal apophysitis resolves, prevention with the use of stretching, good supportive shock absorbing shoes, prefabricated or custom orthotics and heel raises are important to prevent it happening again.

Long Term Consequences

This condition is self limiting - it will go away when the two parts of bony growth join together - this is natural. Unfortunately, it can be very painful and limit sport activity of the child while waiting for it to go away, so treatment is often advised to help relieve it. In very rare cases of calcaneal apophysitis, the treatment is not successful and these children will be restricted in their activity levels until the two growth areas join - usually around the age of 16 years. There are no known long term complications associated with Sever's disease.

